



KINESIOLOGY TAPING FOR HORSES

Relieve pain - optimise movement



Renate Ettl



Acknowledgements

The development of new therapeutic options for horses calls for a wealth of experience, a great deal of patience and also a willingness to experiment. Developing tape applications for such a wide variety of conditions demands a holistic approach to the individual horse. It therefore takes a great deal of time, effort, patience and investment to integrate effective tape applications into a holistic treatment plan.

Many people have been involved in this work and in the project to develop a book on this subject, and I should like to express my heartfelt thanks to them all for their support. In particular, I would like to take this opportunity to warmly thank all those horse-owners who allowed me to take pictures of their horses in compiling the photographs for this book. A very special thank you to Angela Voigt and Franciska Noack – both fully qualified manual and taping therapists – who not only made their horses available for photographs, but also helped me to develop new tape applications.

Many thanks to graphic artist Jeanne Kloepfer for her support in creating the illustrations in this book. My deep gratitude is also due to my husband Peter – who has always supported my book projects in every possible way – particularly for his help in taking photographs of the step-by-step tape applications.

A resounding “Thank you” also to Anna Johne and Maren Warhonorowicz from the Sonntag Verlag publishing house for all their dedication and commitment! And, last but not least, sincere thanks to Jana Mulsow from the company THYSOL Group BV in Enschede (NL) for the amazing support and constructive exchange of knowledge.

Gschaid, Germany, January 2016

Renate Ettl

Table of content

Preface	5
Acknowledgements	6
About the author	10

Part 1

Basic principles

1	The basics of elastic taping for horses	12
1.1	Adhesive tapes in physiotherapy	12
1.1.1	Conventional sport tape	12
1.1.2	Elastic Tape	12
1.1.3	Crosstapes	16
1.2	An outline of the history	17
1.2.1	Clarifying terms	17
1.3	Indications and Contraindications	17
1.4	How taping works	19
1.4.1	The science behind taping	20
1.5	The science of colours	21
1.5.1	The influence of colours	22
1.5.2	The significance of colours in elastic taping	23
1.5.3	The choice of colour	25
1.6	Knowledge of anatomy and physiology	27
1.6.1	The passive musculoskeletal system	27
1.6.2	The Active Musculoskeletal System	28
1.6.3	The Nervous System	31
1.6.4	The lymph system	32
1.6.5	The inner organs	34
1.7	Knowledge of pathology	35
2	The basic tape applications	36
2.1	Basic principles	36
2.1.1	Handling the tapes	37
2.1.2	Tape tension	39
2.1.3	Convolutions	40
2.1.4	Additional anchors	40
2.2	Muscle applications	42
2.2.1	The vector technique	44
2.2.2	The tangential technique	48
2.3	Ligament applications	50
2.3.1	The vector technique for tendon tapes	52
2.3.2	The centring technique	54
2.4	Fascia applications	57
2.4.1	The tangential technique	58
2.5	Functional and mechanical correction applications	60
2.5.1	The vector technique	61
2.6	Nerve applications	64
2.6.1	The vector technique	64
2.7	Lymph applications	65
2.7.1	The fan technique	67
2.7.2	The serpentine technique	67

2.8	Tape applications for scars	69
2.8.1	The cross technique	70
2.8.2	The Z-technique	72
2.8.3	The stairs technique	72
2.8.4	The fascia technique	74
2.9	Segment applications	74
2.9.1	The fan technique	76
2.10	Meridian applications	76
2.10.1	The vector technique	77
2.10.2	Space applications in the centring technique	78
2.11	Combining tape applications	79
2.11.1	The order of the applications	80
2.11.2	“Tape-on-tape” affixing	80
2.12	Summary	83

Part 2

Appraisal strategies

3	The appraisal	86
3.1	The examination procedure before taping	86
3.1.1	Anamnesis	86
3.1.2	Adsppection	87
3.1.3	General health check	88
3.1.4	Gait analysis	89
3.1.5	Palpation	90
3.1.6	Testing techniques	90
3.1.7	Specific examinations	92
4	Treatment techniques	93
4.1	Conventional medical treatment	93
4.2	Manual treatment techniques	93
4.2.1	Muscle therapy treatments	93
4.2.2	Osteopathy and chiropractic	94
4.3	Concomitant therapies	96
4.4	Taping in practice	96
4.4.1	Enhancing the adhesive power of the tapes	97
4.4.2	Preparing the horse	98
4.4.3	Checking the tapes	99
4.4.4	Riding with tapes	101

Part 3

Indication-based applications in practice

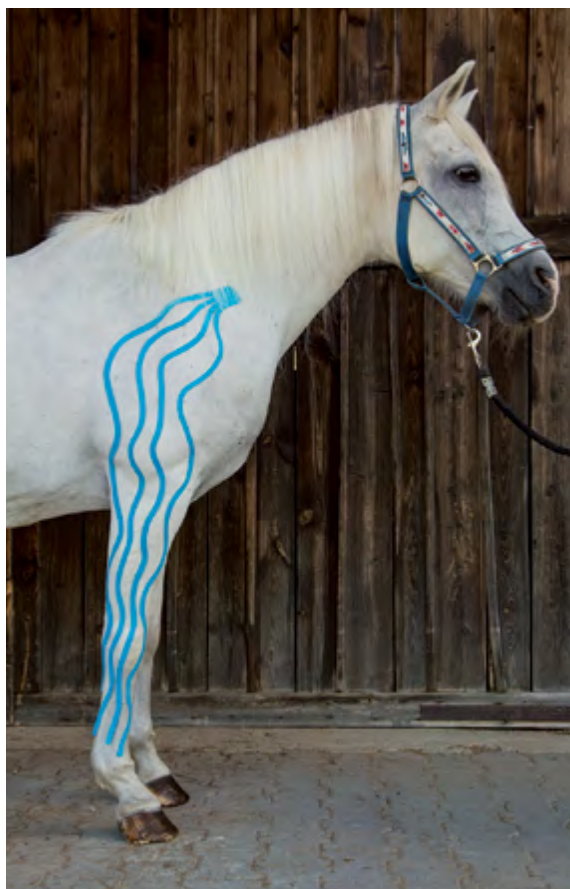5	The clinical use of elastic tapes	104
5.1	Principles	104
5.2	Muscular dysfunctions	105
5.2.1	Spasms and atrophy of the masseter muscle	106
5.2.2	Spasms and atrophy of the caudal oblique muscle of the head	108
5.2.3	Spasms and atrophy of the rhomboid muscle	110
5.2.4	Spasms and atrophy of the brachiocephalic muscle	112
5.2.5	Spasms and atrophy of the trapezius muscle	114
5.2.6	Spasms and atrophy of the longissimus dorsi muscle	116
5.2.7	Spasms and atrophy of the tensor fasciae latae muscle	120
5.2.8	Spasms and atrophy of the semitendinosus and semimembranosus muscles	122
5.2.9	Spasms and atrophy of the biceps femoris muscle	125

5.3	Muscle injuries	127
5.3.1	Haematomas	128
5.3.2	Muscle (fibre) rupture	130
5.4	Tendopathies	131
5.4.1	Injuries of the deep digital flexor muscle (deep flexor tendon)	133
5.4.2	Inflammation of the podotrochlea	136
5.4.3	Shortening of the flexor tendons	137
5.4.4	Injuries of the superficial digital flexor muscle (superficial flexor tendon)	140
5.4.5	Damage to the medial interosseus muscle (suspensory apparatus of the fetlock)	142
5.4.6	Lesions of the Achilles tendon	145
5.5	Ligament lesions	148
5.5.1	Proximal patellar fixation	149
5.5.2	Lateral dislocation of the patella	151
5.5.3	Ligament weakness of the limb joints	152
5.6	Joint lesions on the limbs	154
5.6.1	Arthrosis of the hock (spavin)	155
5.6.2	Arthrosis of the carpal joint	156
5.6.3	Arthrosis of the sacroiliac joint	159
5.6.4	Synovitis	160
5.7	Problems of the vertebral column	163
5.7.1	Kissing spine syndrome	164
5.7.2	Blockage of the cervical vertebrae	167
5.7.3	Malpositions of the thoracic vertebrae and sacrum	169
5.7.4	Hyperlordosis (swayback)	171
5.8	Neurological patterns of disease	174
5.8.1	Radial nerve palsy	175
5.8.2	Paresis of the suprascapular nerve	177
5.8.3	Trigeminal neuralgia (headshaking)	178
5.9	Malpositions	181
5.9.1	Toed-in and toed-out malpositions	181
5.9.2	Base-narrow and base-wide malpositions	182
5.9.3	Combined malpositions	182
5.9.4	Varus and valgus malpositions of the carpal joint and hock	184
5.9.5	The “camped-out in front” and “camped-out behind” malpositions	185
5.9.6	Over at the knee and back at the knee malpositions of the carpal joint	185
5.10	Gait faults and relieving postures	186
5.10.1	Paddling	187
5.10.2	A weight-bearing deficit of the hind limb	189
5.11	Diseases of the lymph system	192
5.11.1	Oedemas	192
5.11.2	Phlegmons	194
5.12	Organic diseases	196
5.12.1	Respiratory diseases	196
5.12.2	Gastrointestinal diseases	199
5.12.3	Detoxification organs	200

Part 4

Appendix

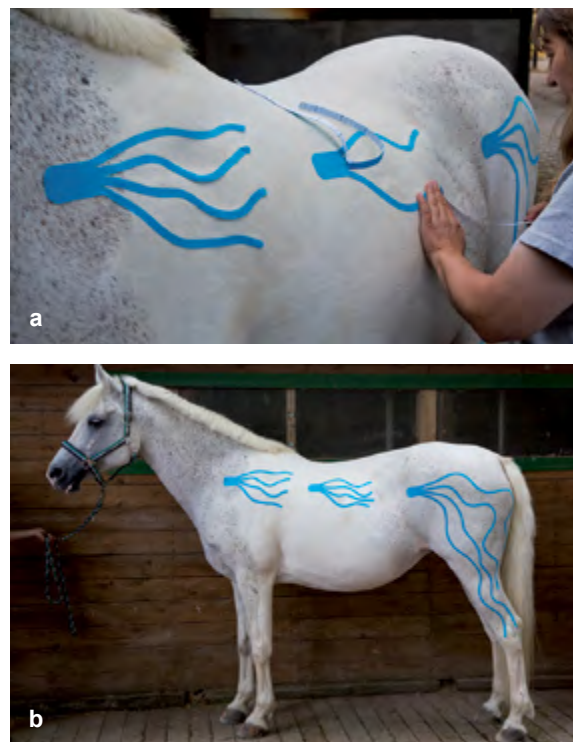
6	Further reading	206
7	List of illustrations	207



► **Figure 2.42** Serpentine lymph tape for decongesting the forelimbs, with starting base on the lymph node centre.

to the next large lymph collection point, or from the lymph node centre to the drainage area, is bridged using a single long tape. The advantage of using the long tape is that there is no interruption of the lymph flow, as the tape arms run continuously. An additional practical aspect is that, with long tape arms, it is possible to affix more extensive wavy lines which cover a larger area, thereby activating the lymph still better (► **Fig. 2.42**).

The preparation of the tape is similar to that in the fan technique, except that fewer but longer tapes are used. You begin by again affixing the tape over the area where the lymph flows into the bloodstream in the region of the left venous angle. After removing its backing paper, the starting base is affixed. Next, after pre-stretching the tissue, the backing paper is peeled off the uppermost tape arm using the paper-off technique, and the tape is affixed in a wavy line, bordering the upper edge of the drainage area. The opposite arm of tape is then affixed in the same way, bordering the opposite side, so that the two arms together enclose the drainage area. The two middle arms of tape are likewise freed of their backing paper using the paper-off technique and affixed in wavy lines, thus filling the space inside the enclosed area. While still pre-stretching the tissue, the bases



► **Figure 2.43** Draining the lymph from the decongestion area to the venous angle.
a Affixing the lymph tape in the fan technique: the outer fan-arms are affixed first, in order to enclose the drainage area.
b Completed lymph application, combining fan lymph tapes and a serpentine tape for decongesting the hindquarters.

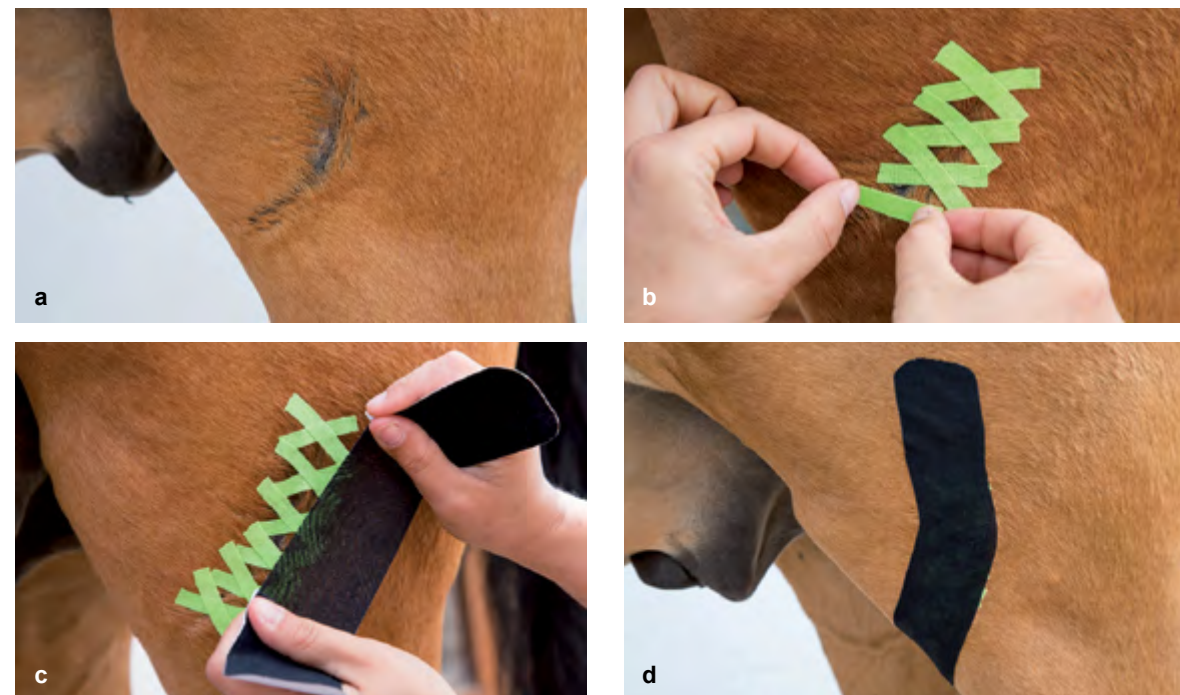
and the arms of the lymph tape are rubbed thoroughly to generate heat for activating the adhesive. After the pre-stretching is brought to an end, the convolutions become visible.

Care must be taken not to affix the arms of the lymph tape on top of one another, as this could reduce the adhesive capacity of the tapes (► **Fig. 2.43**).

Summary

A summary of the facts on lymph applications:

- **Technique:** Fan technique, serpentine technique
- **Indications:** Lymph oedemas, “filled legs”, haematomas, swellings, injuries, pain relief
- **Tape form:** Fan tape, short or long form
- **Tape stretch:** Maximum 10% (paper-off)
- **Pre-stretching:** Light pre-stretching or the skin is pushed forwards.
- **Starting base:** Always at the lymph node centres
- **End base:** Affixed with free ends in the congested area
- **Preferred tape colour:** Blue



► **Figure 2.44** There are many different techniques for taping scars. Here is an example of a treatment for a scar in the region of the knee.
a The scar on the knee is clearly visible.
b The scar is taped with small lengths of tape affixed in X-shapes, as a ligament application in the centring technique.
c The scar is completely covered. Following this, an I-tape (black) is affixed under tension over the X-tapes.
d The completed scar application with black cover tapes.

2.8 Tape applications for scars

There's hardly a horse that has no scars. Every gelding has at least one castration scar and every horse with a breed, identification or registration brand mark will carry that branding scar for its whole life. Then again, additional scars arise through minor and major injuries as well as scars from operations. An injury will always lead to the formation of a scar if the dermis has been injured as well. A scar is always a replacement tissue that is formed by fibroblasts and is densely fibrous in structure. However, it is no longer fully functioning tissue, and can therefore never be a real substitute for intact, healthy skin.

Note

Scar tissue is a lower-quality, densely fibrous replacement tissue which is unable to fulfil the functions of the original healthy skin.

Scars are less profusely supplied with blood, due to which, on human skin, they appear paler than the surrounding tissue. According to the teachings of Traditional Chinese Medicine, scars also hinder the flow of energy and can therefore represent disrupting factors in the overall pattern of functioning of the organism. Cicatrisation (the formation

of scar tissue) is often accompanied by agglutinations in the deeper layers of tissue, resulting in pain and restrictions of the range of movement. For this reason, a scar should be given therapy early on, as soon as the wound has closed.

Aim

Although the large number of collagen fibres do increase the tear resistance of a scar and make the tissue stable, its limited elasticity can however lead to scar ruptures when it is subjected to heavy stresses. Appropriate therapy helps to reduce the negative side effects of cicatrisation to a minimum. Good care helps to keep the tissue supple, and also to minimise agglutinations and improve blood circulation. The resulting harmonisation of the energy flow ultimately helps to bring about pain relief too. The best form of therapy for treating scars, with no contest, is still manual therapy. In between therapy sessions, manual therapy can be supported outstandingly well by means of kinesiology tapes. As a complementary treatment, special kinesiology taping techniques help to achieve optimal sensory and motor function in the area of the scar.

The basics

Every scar differs in shape, depth and alignment, so there are no universally valid rules for applying scar tapes. The type of application chosen always depends on the desired effect, which in turn is based on the state of the scar and

► **Table 5.15** Sedative muscle application for the semitendinosus muscle

Form of application	Preferred colour	Course of tape / Region of body	Technique	Effect, other points
Muscle tape	Blue	Course: semitendinosus muscle via the ischial tuberosity; starting base: high on tibia (below the hollow of the knee) or alternatively on the calcaneus; end base: sacral bone, to the side of the spinous processes	Vector technique, I-tape, without tension, with pre-stretching (protraction of the limb)	Sedative
Muscle tape	Red	Course: enfaming the tensor fasciae latae muscle ; starting base: on the coxal tuber; end bases: below the hip joint on the femur (third trochanter) and also on the cranial edge of the tibia	Tangential technique, Y-tape with max. 25% tension, in light pre-contraction (protraction of the limb)	Toning

► **Table 5.16** Toning muscle application for the semitendinosus muscle

Form of application	Preferred colour	Course of tape / Region of body	Technique	Effect, other points
Muscle tape	Red	Course: semitendinosus muscle via the ischial tuberosity; starting base: sacral bone, to the side of the spinous processes; end base: high tibia (below the hollow of the knee) or alternatively on the calcaneus	Vector technique, I-tape, with max. 25% tension, in light pre-contraction (retraction of the limb)	Toning
Muscle tape	Blue	Course: enfaming the tensor fasciae latae muscle ; starting bases: below the hip joint on the femur (third trochanter) and also on the cranial border of the tibia; end base: on the coxal tuber	Vector technique, 2 I-tapes, without tension, with pre-stretching (retraction of the limb)	Sedative

► **Table 5.17** Sedative muscle application for the semimembranosus muscle

Form of application	Preferred colour	Course of tape / Region of body	Technique	Effect, other points
Muscle tape	Blue	Course: semimembranosus muscle ; starting base: somewhat medial of the hollow of the stifle; end base: os sacrum (tip of the sacral bone)	Vector technique, I-tape, without tension, with pre-stretching (protraction of the limb)	Sedative
Muscle tape	Red	Course: enfaming the tensor fasciae latae muscle ; starting base: on the coxal tuber; end bases: below the hip joint on the femur (third trochanter) and also on the cranial border of the tibia	Tangential technique, Y-tape with max. 25% tension, in light pre-contraction (protraction of the limb)	Toning

► **Table 5.18** Toning muscle application for the semimembranosus muscle

Form of application	Preferred colour	Course of tape / Region of body	Technique	Effect, other points
Muscle tape	Red	Course: semimembranosus muscle ; starting base: os sacrum (tip of the sacral bone); end base: somewhat medial of the hollow of the stifle	Vector technique, I-tapes, with max. 25% tension, in light pre-contraction (retraction of the limb)	Toning
Muscle tape	Blue	Course: enfaming the tensor fasciae latae muscle ; starting bases: below the hip joint on the femur (third trochanter) and also on the cranial border of the tibia; end base: on the coxal tuber	Vector technique, 2 I-tapes, without tension, with pre-stretching (retraction of the limb)	Sedative

5.2.9 Spasms and atrophy of the biceps femoris muscle

The tendon-muscle attachment of the biceps femoris muscle not only provides an extension running to the Achilles tendon, but also covers the stifle from the lateral side. For this reason, in the case of horses that react sensitively to palpation in the region of the stifle, the therapist should also consider an impairment of the biceps femoris muscle as a possible cause. As a synergist to both the semitendinosus muscle and the semimembranosus muscle, the biceps femoris muscle often reacts together with them when the “semis” are overstrained. Besides causing difficulties in building up forward impetus, lesions of the muscles also result in problems with moving sideways, as well as a shortened stride.

Anatomical facts

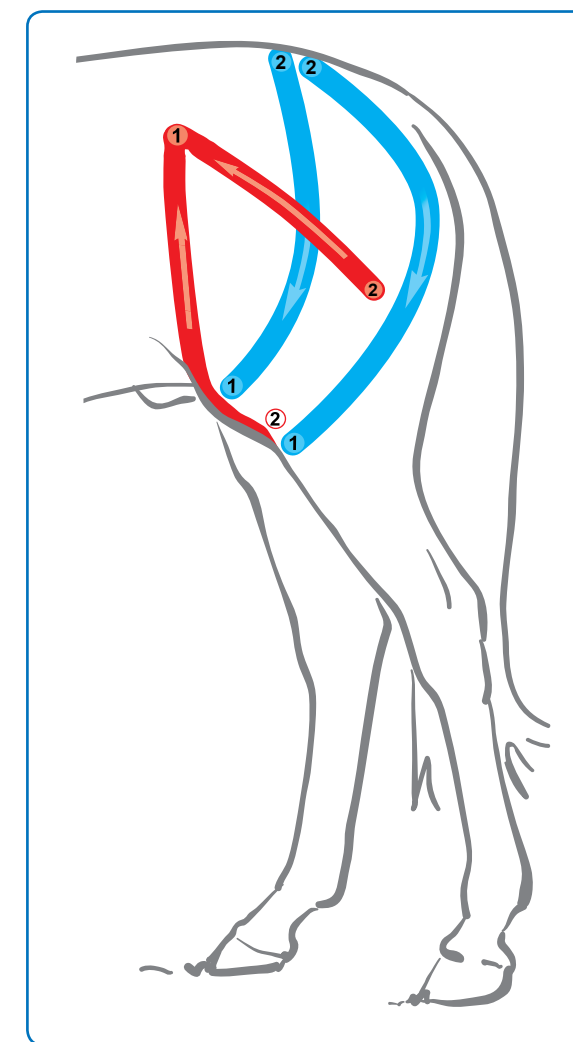
- **Muscle origin:** Sacrum (spinous and transverse processes), broad sacrotuberous ligament, caudal fascia, ischial tuberosity
- **Muscle attachment:** Patella, intermediate and lateral patellar ligament, tibial cranial margin, common calcaneal tendon, calcaneal tuberosity
- **Function:** Stretching and abduction of the hip joint, flexing the stifle in the swing phase, and extension of the stifle joint and hock in the weight-bearing phase
- **Innervation:** Caudal gluteal nerve, tibial nerve
- **Antagonist:** Tensor fasciae latae muscle and quadriceps femoris muscle

► **Figure 5.26** A sedative I-tape affixed on the semitendinosus muscle with pre-stretching.

Example of a tape application for the biceps femoris muscle

The biceps femoris muscle, which consists of two parts, occupies the space cranially of the semitendinosus muscle all the way to the front edge of the femur and, due to its shape, can be enframed with a Y-tape. For a toning application, the starting base is attached over the transverse processes of the sacrum, and the arm of tape that is located cranially is pulled all the way to the knee, while the arm of tape located caudally is pulled either to a point below the stifle or to the hollow of the stifle. In the latter version, the end base is affixed at the calcaneus.

For the relaxing application, two I-tapes that meet at the sacral bone, without however being affixed on top of each other (► **Fig. 5.27**), offer a better alternative. Another option is to attach a single I-tape over the muscle belly – preferably following the course of the cranial portion – from the stifle to the sacral bone, running between the hip joint and the ischial tuberosity.

► **Figure 5.27** Schematic diagram of the standard sedative tape application for the biceps femoris muscle with a toning application for its antagonist, the tensor fasciae latae muscle.

tant to check whether the horse has a correct hoof position. In certain cases, the vet can also administer an injection into the knee cap ligament to tightening it.

If there is a risk that the proximal patellar fixation could repeatedly occur, the very first measure should be a training plan for building up the quadriceps muscle (► Fig. 5.49).

Examples of tape applications for a proximal patellar fixation

Unfortunately, due to equine conformation, it is difficult to design a targeted tape application. Basically, one would have to lay a strengthening muscle application for the quadriceps muscle, and to additionally place a ligament tape over the medial patellar ligament; however, as these structures cannot be reached directly, the ideal tape application remains somewhat hypothetical.

This is why we need to try other approaches. In the best case, the medial and lateral regions of the knee joint can be given taping therapy. In addition, the superficial muscles, which function as synergists of the quadriceps muscle, can be given a toning tape application.

In order to bring about stabilisation of the patella, a ligament tape is attached over the lateral and intermediate patellar ligament using the centring technique. In addition, the synergists of the quadriceps femoris muscle (tensor fasciae latae muscle and the cranial portion of the biceps femoris muscle) can be given a toning muscle application and its antagonists (caudal portion of the biceps femoris muscle, gastrocnemius muscle and popliteal muscle) can be given a sedative muscle application (► Fig. 5.50).



► **Figure 5.51** Implemented tape application for indirectly strengthening the quadriceps muscle in a case of proximal patellar fixation in a Shetland pony. The tensor fasciae latae muscle and the cranial portion of the biceps femoris muscle have been given an activating tape application (red). The caudal portions of the biceps femoris muscle and the gastrocnemius muscle have received a sedative muscle application (blue), partly affixed with anchor tapes (black). In addition, a lateral and medial ligament tape (pink) has been attached to stabilise the knee cap ligament.

► **Table 5.31** Tape application for proximal patella fixation

Form of application	Preferred colour	Course of tape / Region of body	Technique	Effect, other points
Muscle tape	Red and blue	Course of the biceps femoris muscle , red I-tape: on the cranial muscle and caudally around the hip joint all the way to the knee; starting base: sacral bone; end base: patella, blue I-tape: on the caudal edge of the muscle all the way to sacrum; starting base: tibia, end base: sacrum	Tangential technique with 2 I-tapes (red and blue), with max. 10% tension, with pre-stretching (protraction of the limb) for affixing the blue tape and neutral position and 25% tension for affixing the red tape on the cranial part.	Cranial portion: toning; caudal portion: sedative
Muscle tape	Red	Enframing the tensor fasciae latae muscle , starting base: coxal tuber; end bases: tibia and third trochanter of the femur	Tangential technique with Y-tape, with max. 25% tension, with light contraction (protraction of the limb)	Toning (helps to extend the knee and to bring the limb forwards)
Muscle tape	Blue	Course: on both muscle bellies of the gastrocnemius muscle ; starting base: calcaneus; end bases: femur	Vector technique with Y-tape (on the lateral and medial heads), with max. 10% tension with forward stretching (protraction of the limb)	Sedative
Ligament tape	Black, violet, red	Region: running along the course of the medial, intermediate and lateral patellar ligaments; bases proximal of the patella as well as proximal third of the tibia	Centring technique with up to 100% tension running along the course of the knee cap ligaments	Tightening

Aim

To strengthen the medial and lateral ligaments in order to stabilise the patella, and to support the building up of the quadriceps femoris muscle through its synergists, and to relax its antagonists (► Fig. 5.51, Table 5.31).

Step by step

- Calculate the length of the required tape(s) (I-tape, Y-tapes), pre-cut, round off the corners.
- Prepare one red and one blue I-tape for the biceps femoris muscle. Attach the red tape starting from the sacrum in an arc (along the cranial edge of the muscle) all the way to the patella, with up to max. 10% tension, affix the ends without tension, and rub the tape down well.
- Affix the blue I-tape with the starting base at the level of the tibia, stretch the limb forward and draw the tape along the caudal edge of the muscle, all the way to the sacrum. Attach the end base and rub the whole tape down well, then allow the limb to return to the resting position (formation of convolutions).
- Affix the red muscle tape in a Y-form with the starting base on the coxal tuber (tuber coxae), then attach the tape arms to run along the course of the muscle as far as the tibia, or third trochanter of the femur if necessary. Use light contraction (protraction of the limb), with a max. 25% tension, apply the bases without tension, and activate the adhesive by rubbing.
- Affix the blue Y-tape with the starting base on the calcaneus and rub the tape down well. Now draw both arms of tape over the muscle belly of the lateral head and medial head respectively, with simultaneous forward stretching (protraction of the limb), all the way to the muscle origin. Apply with max. 10% tension (paper-off technique) and tape ends without tension. Rub the tape down well.
- Make a tear in the middle of the backing paper of the ligament tapes (preferred colour: black) and affix en bloc over the knee cap ligaments (lateral and medial), using the centring technique, with up to 100% tension. Attach ends (proximal of the patella as well as tibia) without tension and activate the adhesive by rubbing.

5.5.2 Lateral dislocation of the patella

In a luxation of the patella, the knee cap springs out of its groove. It can thereby become permanently displaced or spring back into its groove. The patella can be displaced both laterally and medially, although the lateral dislocation occurs much more frequently. This is why only the lateral luxation of the patella is discussed here.

Causes

A lateral dislocation of the knee cap usually occurs due to an injury through the overstretching or rupture of the medial straight patellar ligament. In small breeds of pony (Shetland ponies, ► Fig. 5.53), loose knee cap ligaments and the lateral dislocation of the patella associated with them, can be caused by an autosomal-recessive hereditary process. Such ponies should not be used for breeding.

Symptoms

In the case of a lateral patellar luxation that presents as a static displacement, the result is a flexed position of the knee and hock. It is not possible for the horse to put any weight on that limb. The permanent lateral patellar luxation is usually associated with an atrophy of the quadriceps muscle.

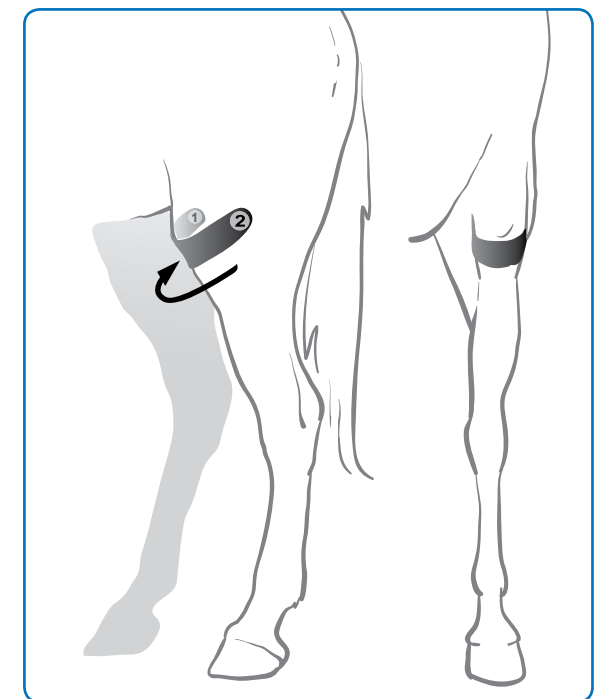
As soon as the horse or pony puts weight on the limb, the patella jumps out of the groove above the lateral epicondyle. Often, it slips back into the groove again shortly afterwards. However, this thereby causes a flattening of the groove and of the lateral epicondyle, if that is not already a congenital condition.

Therapy

In the case of the lateral knee cap luxation, the therapeutic aim is to weaken or deactivate the fasciae, ligaments and muscles which are pulling the patella in a lateral direction. In severe cases, this is done through an operation. In milder cases, a tape application can reduce the tension of the structures, thus minimising the probability of a displacement of the patella.

Examples of tape applications for a lateral patellar luxation

The aim is to stabilise the patella in its groove. This can be attempted with a correction tape attached below the knee cap and over the patellar ligaments. The pulling tension of the tape is thus aligned to medial, in order to head off or reduce the tendency of the body's own structures to pull in a lateral direction (► Fig. 5.52).



► **Figure 5.52** A supportive tape application for stabilising the patella in its groove. For this application, a correction tape is attached from medial to lateral under high tension, in order to achieve a medial direction of pull (arrow).



KINESIOLOGY TAPING WORKS!

The elastic adhesive tapes support movement without restricting it. By means of microtraction, they deliver healing stimuli to the body, which optimise movement and relieve pain.

Taping helps, for example, in cases of painful changes in muscles and joints, or when horses display postural or gait faults – either as a way of supporting physiotherapy or as a stand-alone treatment method. This book offers you an in-depth look at the many and varied options for applying kinesiology tapes:

- Beginning with a sound, thorough examination procedure involving gait analysis, palpation and specific tests, you can precisely locate problems in the horse's tissue.
- The knowledgeable information on adapting the cut, colour and degree of tension of the elastic tapes enables you to deploy them in a targeted, individual treatment for each horse.
- Suitable tape applications for over 50 patterns of disease (muscle tapes, correction tapes, fascia tapes, etc.) and the different taping techniques (e.g. I-tapes, Y-tapes and crosstapes) are described in detail.
- The richly illustrated step-by-step guidance sections make it easy to put each tape application into practice.




THYSOL Group BV
Midzomerweg 8
7532 SW Enschede
The Netherlands
Telephone +31 53 206 8040



www.vetkintape.com

ISBN 978-90-825826-0-4



9 789082 582604